

Palmar digital nerve block

Volume of local anesthetics: 1,5 ml at each site.

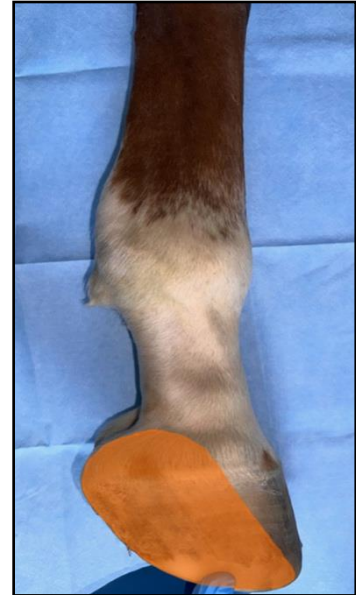
Performed when the limb is held.

Anesthetized nerves: n. digitalis palmaris/n. digitalis plantaris

Sometimes is called as the „heel block“.

Desensitized structures:

- the sole, the soft tissue of the heel
- the navicular apparatus
- the coffin joint
- the distal part of the deep digital flexor tendon
- the distal sesamoidian ligaments

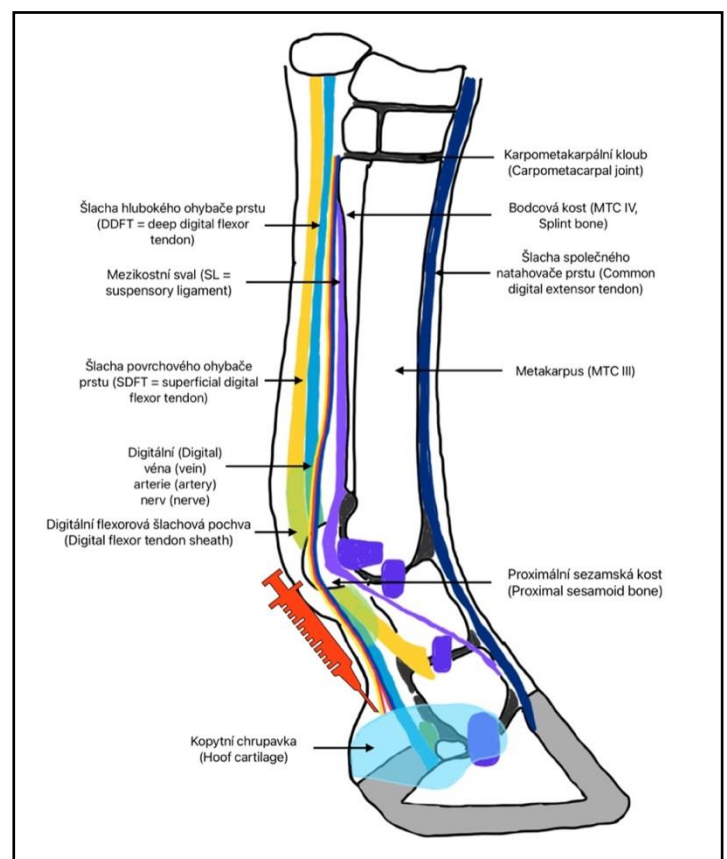


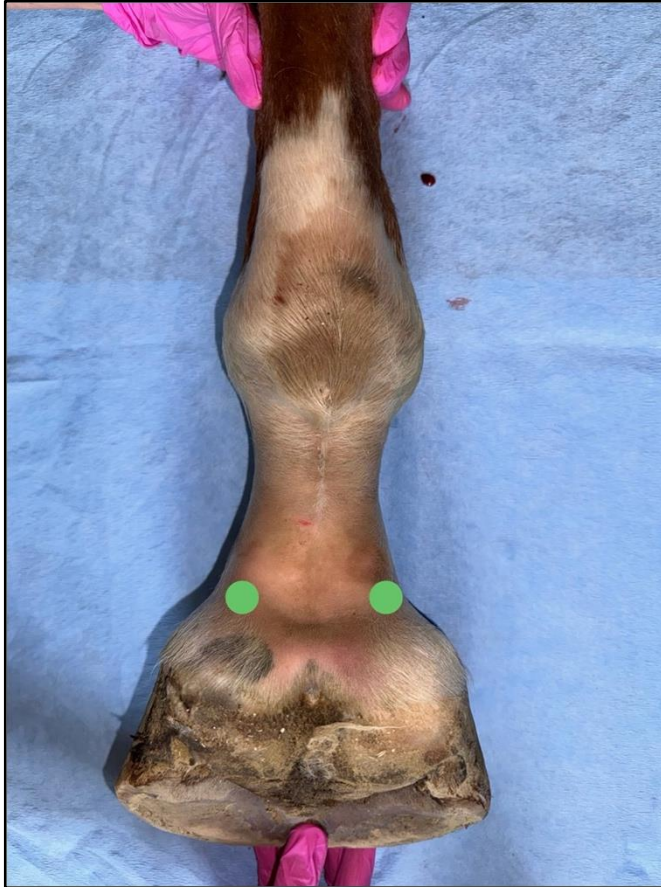Injection technique:

The needle is inserted directly over the palmar side of the neurovascular bundle, over the foot cartilage.

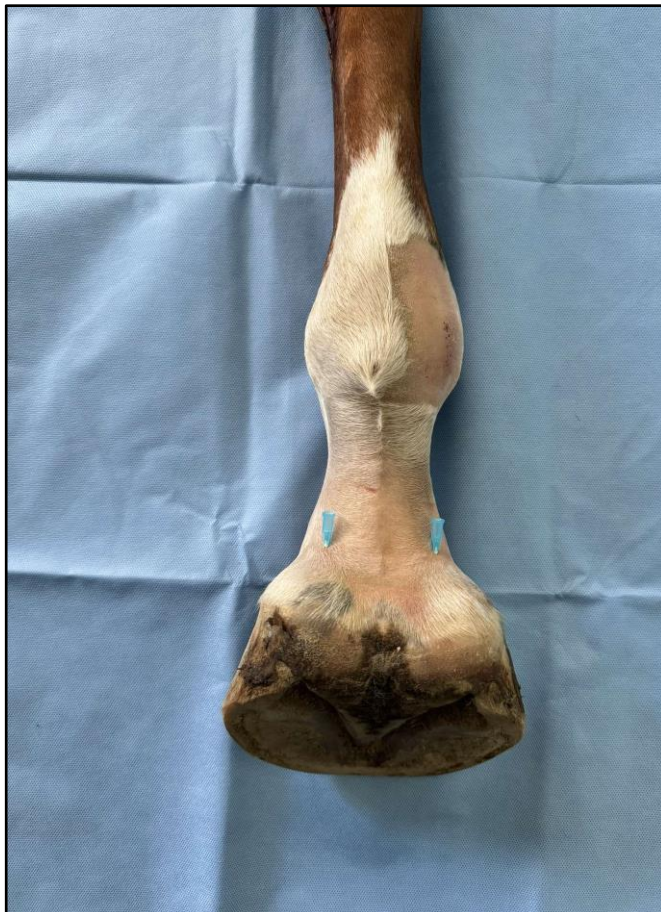The neurovascular bundle is palpable about 1 cm above the cartilage of the foot.

The needle is inserted in a distal direction.





Neurovascular bundle is palpable at each site of the limb, 1 cm over the foot cartilage.



The needle is inserted from lateral and medial site in a distal direction, over the foot cartilage.